


Follow up :-

गौरी रायस्य वर लेख

अध्याय क्र० ३२३ मध्ये ~~अध्याय क्र० ३२३ मध्ये~~

अध्याय क्र० ३२३ मध्ये ~~अध्याय क्र० ३२३ मध्ये~~

110x1x020 Biopsy finding 

Biopsy shows epidermal hyperplasia & marked orthokeratotic hyperkeratosis & church spire like papillomatosis and focal epidermal digitation & separation of stratum corneum. Spinous layer upper dermis in basal and spinous layer upper dermis shows mild chronic inflammatory cell infiltration

Attending Advice  
मेरी डाक्टरों से चर्चा, अल्ट्रासाउंड  
डाक्टरों से चर्चा और बॉडी  
C.J. Press, Raipur (C.G.)  
लखनऊ

DR. B.R. AMBEDKAR MEMORIAL  
HOSPITAL RAIPUR (C.G.)  
**DISCHARGE TICKET**  
DEPARTMENT OF ... Skin and VD

UNIT .....  
Name... Jageshwari D/o. Godali.  
Age... 8 years Sex Female Caste.....  
Address... Kunguan, Dantewada, C.G.  
Ward/Bad No. Private ward Weight.....  
Date of Admission... 19.10.13<0 Reg. No. 020354  
Date Discharge... 16/02/2020 Ind. No. 8002912  
Diagnosis... Icthyosis histrix  
Result... Discharge.....

Condition of Adm. :-

Old body thick painful lesion present all over limbs and abdomen since child hood. [for 8 years]

Who presenting illness - 8 year old Jageshwari presented with massive thick orthokeratotic plaque to verrucous massive like appearance this plaque symmetrical over upper limb and lower limb even palm face side.

Condition of Discharge :-

• Pt is conscious -> fine plastic cerebellar tremor

• Pulse - 60/min

• BP - 110/60 mmHg

• RR - 30/min

• Temp - 4 Febrile

• CVS - 2/2 + Jt, Normotensive

• CNS - No known deficit

• RS - ABE OE, No added sound + Jt

• RA - soft non tender

• CBC - WBC - 4.10 Biopsy - (I) on 20/01/2020

Hb - 9.24  
 PLT - 232  
 Impression - Ecthymosis  
 Hysteric

• Ferritin - 198.1  
 • Vit D - 10.77  
 • Vit B12 - 10.02  
 • TSH - 4.22

• T3 - 2.00  
 • T4 - 10.02  
 • TSH - 4.22  
 Impression - Ecthymosis  
 Hysteric

• U & P - 141ML  
 • X-Ray Sacro-ligament - No significant abnormality

• X-Ray Sacro-ligament - No significant abnormality

Treatment Given :-

• High protein diet

• Tab Vit A - 1-00

• 500mg Zinc glutamate 5ml BD

• 500mg Cal + vit B3 5ml TDS

• 500mg Iron 2.5ml - 1-00

• 500mg Amoxyclove 2ml - TDS

• MS compression over plaque BD

• Emol-ds lotion over thick plaque

• Azon urea cream over plaque

• Fusidic acid cream VA ± sachet weekly

• Vit D3 Sachets 1 sachet weekly

• Treatment Advised :-

• As advised by GI Dermatology.

• High protein Diet x 1 month

• 500mg Cal + vit D3 5ml TDS x 1 month

• 500mg Iron 5ml BD x 1 month (5ml -> 25mg)

• 500mg Zinc glutamate 5ml BD x 1 month

• Emol-ds lotion over thick plaque (morning)

• Wiped lotion over thick plaque (Evening)

• Azon urea - 1% Cream VA TDS  
 1% MF-urea / Penicillin cream  
 Fusidic acid cream VA - BD for 7 days  
 Sofamycin  
 Vit D3 Sachet once weekly for 3 months



डा. सामराव अम्बडकर स्मृत चिकित्सालय, रायपुर (छ.ग.)

प्र. जवाहर लाल नेहरू स्मृति चिकित्सालय महाविद्यालय रायपुर से सम्बद्ध चिकित्सालय

UHID/Reg. No. 2020-01-022252 Reg. Date & Time 20-01-2020 12:34:07 pm  
Patient Name: GODRU RAM Age / Sex : 32 Y 0 M 0 D / MALE  
Fath./Husb. Name: S/O FAGU RAM Patient Type: PAID / PAID  
DOCTOR: DR HANSA BANJARA Aadhaar No :  
DEPARTMENT: ENT-244 Mobile No :  
Smart Card : NO

Patient Address: KORGAON DANTEWADA C.G  
Remark:

MLC / NON MLC (C- )  
REG. CHARGES 10 /-  
User : Nirmal Pradhan




2020-01-022252

अभिरोग, रतिज्वर, कुष्ठरोग ओ.पी.डी.  
पं.ज.ने.मै.मेडिकल कॉलेज एवं  
बी.आर.ए.एम.अस्पताल, रायपुर (छ.ग.)

ओ.पी.डी. क्रं. 20/01/2020  
दिनांक

रोग/कुष्ठ



Tab Amoxyclo 625mg 1 B/D  
सुबह रात

Tab omeprazole 20mg 1 B/D  
सुबह रात (खाने पके)

Puridic acid cream दो बार

Tab (72 10mg 1 B/D रात)

2 days

cas c / mp  
v m, n m, s  
widom  
J L m  
Dengue

कृपया ध्यान रहे चिकित्सालय आते समय यह कार्ड लाना न भूले।  
कृपया चिकित्सालय में स्वच्छता बनाये रखे।  
शौचालय का उपयोग करे।  
टोल फ्री नं. 104 पर दवा प्राप्त न होने पर सूचित करे।



DR B R A M COLLEGE  
RAIPUR

CLINICAL PATHOLOGY  
PATHOLOGY LAB

Specimen ID: 78  
Patient ID:  
First Name:  
Run Date/Time: 22/01/2020 01:26 PM  
Collection:  
Location:  
Comments:

Test  
Gen  
Las  
Dat  
Seq  
Phy

**Dr. B.R. Ambedkar Memorial Hospital  
RAIPUR (C.G.)**

**REQUISITION FOR LABORATORY TESTS**

UHID/Reg. No. 022252

Name Godru Ram Age/Sex 32/M

Wd/Bed/OPD Mo PD Free/Paid

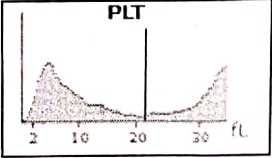
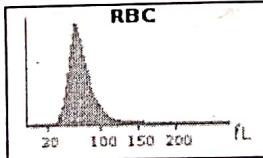

Diagnosis

Investigations Required :- CBC CPS 78 for MP

Date: 22/1/20 R.M.O./ Consultant

Test	Result	Flags	Units	Low	High
WBC	6.85		x10 <sup>3</sup> /μL	3.60	10.20
LY	16.38		%	15.20	43.30
MO	10.45		%	5.50	13.70
NE	68.06		%	43.50	73.50
EO	4.73		%	0.80	8.10
BA	0.39		%	0.20	1.50
LY#	1.12		x10 <sup>3</sup> /μL	1.00	3.20
MO#	0.72		x10 <sup>3</sup> /μL	0.30	1.10
NE#	4.66		x10 <sup>3</sup> /μL	1.70	7.60
EO#	0.32		x10 <sup>3</sup> /μL	0.00	0.50
BA#	0.03		x10 <sup>3</sup> /μL	0.00	0.10
RBC	3.55		x10 <sup>6</sup> /μL	4.06	5.63
HGB	8.71		g/dL	12.50	16.30
HCT	27.1		%	36.7	47.1
MCV	76.2		fL	73.0	96.2
MCH	24.5		pg	23.9	33.4
MCHC	32.1		g/dL	32.5	35.1
RDW	16.9	h	%	12.1	16.2
RDW-SD	43.2		fL	36.5	46.0
PLT	68.4	R	x10 <sup>3</sup> /μL	152.4	347.9
MPV	8.42	R	fL	7.40	11.40

Flags:  
Suspect  
PLT3: PL



Anisocytosis	
Poikilocytosis	
Polychromasia	
Hypochromasia	
Microcytosis	
Macrocytosis	
Other	
Reviewed by	



Specimen ID: 78  
Patient ID:  
First Name:

Test: CD  
Gender: U  
Last Name:

Specimen: WB

Run Date/Time: 22/01/2020 01:26 PM  
Collection:  
Location:  
Comments:

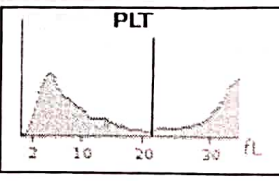
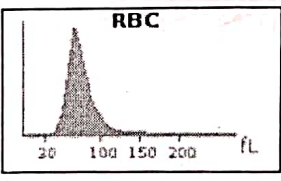

Date of Birth:  
Sequence #: 33191  
Physician:

Age:

Test	Result	Flags	Units	Low	High
WBC	6.85		x10 <sup>3</sup> /μL	3.60	10.20
LY	16.38		%	15.20	43.30
MO	10.45		%	5.50	13.70
NE	68.06		%	43.50	73.50
EO	4.73		%	0.80	8.10
BA	0.39		%	0.20	1.50
LY#	1.12		x10 <sup>3</sup> /μL	1.00	3.20
MO#	0.72		x10 <sup>3</sup> /μL	0.30	1.10
NE#	4.66		x10 <sup>3</sup> /μL	1.70	7.60
EO#	0.32		x10 <sup>3</sup> /μL	0.00	0.50
BA#	0.03		x10 <sup>3</sup> /μL	0.00	0.10
RBC	3.55		x10 <sup>6</sup> /μL	4.06	5.63
HGB	8.71		g/dL	12.50	16.30
HCT	27.1		%	36.7	47.1
MCV	76.2		fL	73.0	96.2
MCH	24.5		pg	23.9	33.4
MCHC	32.1		g/dL	32.5	35.1
RDW	16.9	h	%	12.1	16.2
RDW-SD	43.2		fL	36.5	43.0
PLT	68.4	RI	x10 <sup>3</sup> /μL	152.4	347.9
MPV	8.42	R	fL	7.40	11.40

Flags & Messages	
Flags:	
Suspect Diff	
PLT3: PLT/RBC Overlap	

Neutrophils	
Segmented	
Band	
Lymphocyte	
Monocyte	
Eosinophil	
Basophil	
Metamyelocyte	
Myelocyte	
Promyelocyte	
Blast	
Ab. Lymph	
Other	
NRBC	
Anisocytosis	
Poikilocytosis	
Polychromasia	
Hypochromasia	
Microcytosis	
Macrocytosis	
Other	
Reviewed by	



बाँयोकेमेस्ती खिजकी नं. 1

22/01/2020

टोकन नं. OPD 117

al Hospital

Y TESTS

144

Age/Sex ..... 32/1m

Wd/Bed/OPD ..... B.O.P.D ..... Free/Paid .....

Diagnosis ..... W-8

Investigations Required :-

Wd/Bed/OPD ..... B.O.P.D ..... Free/Paid .....

Wd/Bed/OPD ..... B.O.P.D ..... Free/Paid .....

Date : ..... 22/1/20

R.M.O./ Consultant

Dr. B.R. Ambedkar Memorial Hospital  
RAIPUR (C.G.)

REQUISITION FOR LABORATORY TESTS

UHID/Reg. No. ....

222252

41

152

Name ..... Godiya Ram Age/Sex ..... 32/1m

Wd/Bed/OPD ..... B.O.P.D ..... Free/Paid .....

Diagnosis .....

Investigations Required :-

Wd/Bed/OPD ..... B.O.P.D ..... Free/Paid .....

Date : ..... 22/1/20

R.M.O./ Consultant



**Dr. B.R. Ambedkar Memorial Hospital**  
**RAIPUR (C.G.)**

144



**REQUISITION FOR LABORATORY TESTS**

UHD/Reg: No. .... 022252 .....

Name ..... Godny Ram Age/Sex ..... 32/M

Wd/Bed/OPD ..... B.O.P.D. .... Free/Paid .....

Diagnosis ..... W.B

Investigations Required :- Hospital Test

U.S. MALSS

Date : ..... 22/1/20 ..... R.M.O./Consultant

DEPARTMENT OF ~~CLINICAL~~ PATHOLOGY  
DR. B. R. AMBEDKAR MEMORIAL HOSPITAL, RAIPUR (C.G.)

PATIENT NAME \_\_\_\_\_ S/NO \_\_\_\_\_ A/S \_\_\_\_\_ WD/BED/OPD \_\_\_\_\_

DATE \_\_\_\_\_

URINE EXAMINATION

PHYSICAL EXAMINATION

Amount ..... 10 ml  
Appearance ..... Turbid

CHEMICAL EXA

Albumin ..... +

MICROSCOPIC EXAMINATION

Bug Cells ..... 2-4 /HPF  
Epithelial Cells ..... 2-4 /HPF  
Crystal ..... /HPF

Colour ..... Yellow  
Reaction ..... Acidic

Sugar ..... Nil

R.B/C ..... /HPF  
Casts ..... Nil  
Others ..... Nil

2 Medical Officer

2